

## DYNAVISC®

Adhesion Barrier Gel  
for Tendon and Peripheral Nerve Surgery

## CASE REPORT

### Hand Tumor Resection

Patient had tumor on the lumbrical muscle inside carpal tunnel on right hand.



**Dr. Gustavo Mantovani Ruggiero**  
São Paulo, Brazil

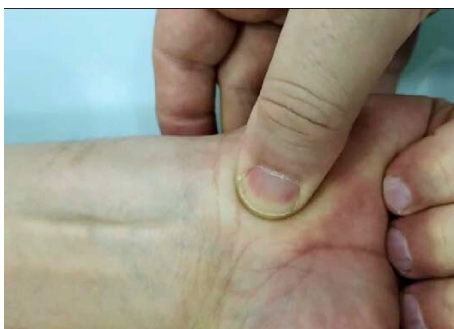- Graduate of Medical Sciences of Santa Casa de São Paulo, specializing in Orthopedics and Traumatology
- Director of the annual Theoretical and Practical Course on Wrist and Elbow Arthroscopy at IRCAD Latin America
- Guest foreign professor at the University of Milan (Italy)
- Member of the Brazilian Society of Orthopedics and Traumatology and the Brazilian Society of Hand Surgery

### Case Introduction

The patient experienced right-hand paresthesia and pain for two months around the median nerve and a “clunk” sound on the wrist upon flexion of his fingers.

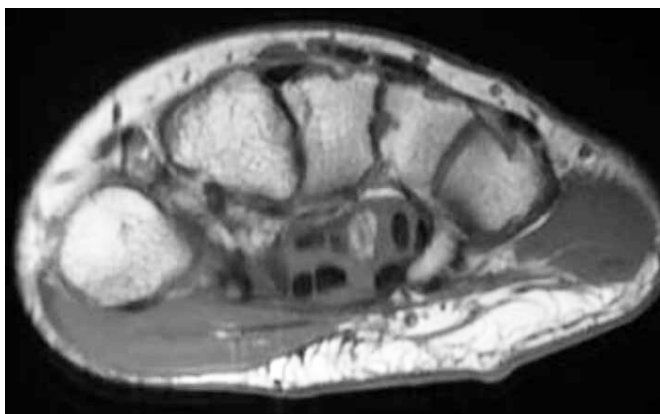
### Case Presentation

Physical examination testing included Tinel, Phallen, Digit Compression, and Scratch Collapse Tests, which were all positive for carpal tunnel syndrome, including the noticeable “clunk” sound during flexion and extension of the fingers, with a triggering sensation on the carpal tunnel level.



Confirmatory exams included, EMG positive for median nerve compression on the carpal tunnel, and ultrasound showing a tumor inside the carpal tunnel and adherent to 4-5 finger's flexor tendons.

Pre-operative palpating the location of the “clunk” and triggering during the flexion and extension of the fingers.



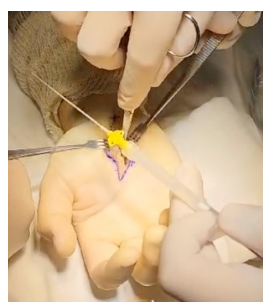MRI showed the tumor inside the lumbrical muscle on the 4th finger flexor profundus tendon suggesting lipomatous origin.

# Hand Tumor Resection

## CASE REPORT

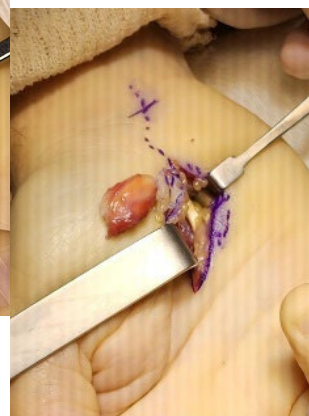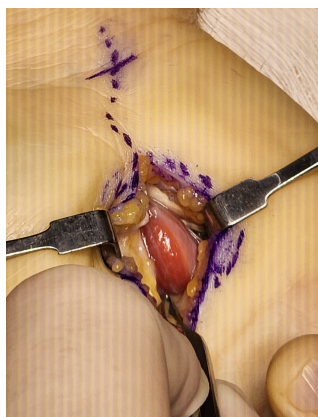
### Operative Approach

Surgery was performed in June 2023, with open carpal tunnel exploration and identification of the tumor. The tumor was resected as a block with the tumors surrounding lumbrical muscle fibers.

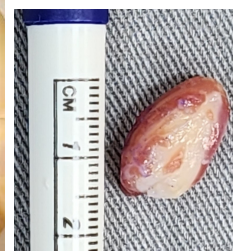

After the resection, Dynavisc® Adhesion Barrier Gel (FzioMed, California, USA) was applied inside the wound, between all flexor tendons and the median nerve.

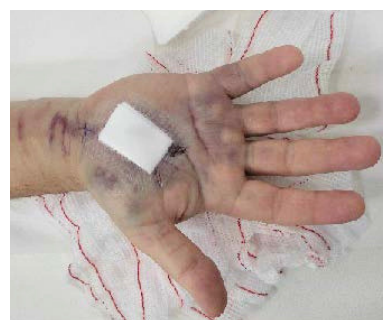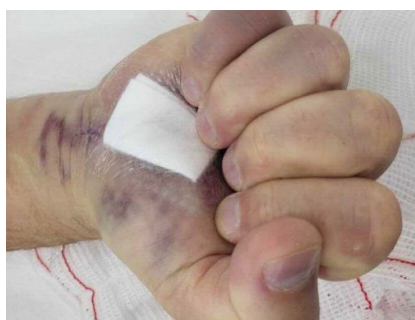[Link to Dynavisc application VIDEO](#)



[Link to Operative Approach VIDEO](#)



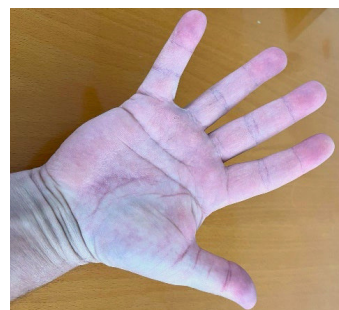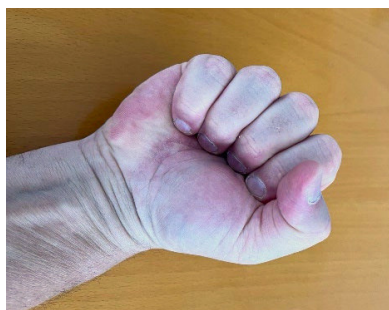### 3 Days Follow-Up



Wound healing and functional recovery were excellent, with complete range of motion recovered three days post-op.

At six weeks follow-up the wound was completely healed and the patient achieved normal function of the hand, including full extension and flexion of all fingers. No pain or neurological symptoms were present. The histopathology demonstrated a benign tumor with the diagnosis of a lipoma.

### 3 Months Follow-Up



Three months post op clinical evolution, final result and function after surgery. This included full extension and flexion of all fingers.

### Discussion

The patient obtained complete functionality of his hand following a tumor resection in the lumbrical muscle. Dynavisc Adhesion Barrier Gel provided an improved result for the patient in terms of functional recovery and pain relief.